

Integrated Cluster Analysis of DTI and MRSI for Brain Tumors

Z. Torbatian¹, and H. Soltanian-Zadeh^{1,2}

¹Electrical and Computer Engineering, University of Tehran, Tehran, Iran, ²Radiology, Henry Ford Health System, Detroit, MI, United States

Introduction

Determination of the grade and type of brain tumors is essential to effective treatment of the patient. Although brain tumors can be characterized using biopsy, the non-invasive methods are under investigations. Magnetic resonance spectroscopic imaging (MRSI) and diffusion tensor imaging (DTI) have provided promising results in differentiation of different types of tumors and normal tissues. MRSI, a non-invasive technique, is beneficial in brain tumor characterization [1]-[2]. It provides biochemical information of the tissue that is helpful in distinguishing brain abnormalities from normal tissues [1]. DTI is another new technique which measures water diffusion anisotropy of a tissue. In anisotropic medium, a 3x3 diffusion tensor matrix (D) should be calculated from DTI provided in at least six directions [3] that its features inform about the magnitude and direction of water diffusion [3], [4]. Based on MRSI capability in characterizing of brain tumors, we used a fuzzy c-means (FCM) classifier in order to detect abnormality in glioma patients. The algorithm failed to detect some abnormalities. According to the results of previous investigations, we hypothesized that the integration of DTI and MRSI features may improve the abnormality detection. The aim of this work is to further develop the proposed algorithm in [5] to integrate MRSI and DTI findings in distinguishing various types of tumors from normal tissues non-invasively, compare the brain tumors MRSI and DTI characteristics to those of the normal tissues, and evaluate the impact of MRSI and DTI integration on the results.

Materials and Method

In this work, 20 patients affected by four different brain glioma tumors were studied. The MRSI were acquired on a 3 T GE Signa System using 2D CSI (32x32 matrix) H-MRSI pulse sequences and DTI (256x256 matrix) were provided with gradient applied in 25 directions and b=1000. T2-Weighted MRI was also available for all patients. MRSI signals were processed using Eigttool image analysis software (Henry Ford Health System, Detroit, MI). The normalized metabolites with respect to normal Creatine (nCr) were computed for each slice. The DTI parameters (mean diffusivity (MD), fractional anisotropy (FA)) were calculated using DTI Studio software (Johns Hopkins University, Baltimore, MD). All the metabolite maps and DTI were registered to the T2-weighted MRI in order to compare the detected abnormality location with its anatomical reference. A FCM classifier was used to cluster image voxels based on normalized Cho/NAA and MD values into four classes. According to previous investigations, the cluster with the highest Cho/NAA center would be suitable to detect high grade tumors and viable tumors. On the other hand, the cluster with the highest MD center detects low grade tumors or necrosis. Since the abnormality may contain different types and grades of brain tumors, both clusters should be processed in order to find the suspicious regions on each of them and compare the results to detect the abnormal tissue. Some post-processing steps were done to detect the most suspicious region on each cluster. To this end, the suspicious region with higher similarity to circle was chosen as the abnormality. The detection for a GBM tumor with extensive necrosis on the right lobe of the brain is shown in the figure.

Result

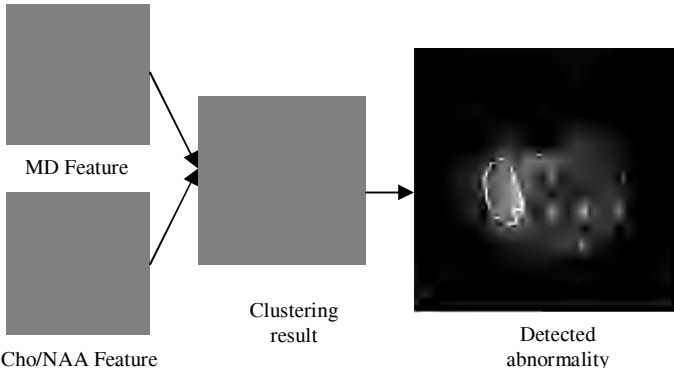
The proposed method was applied to the real data and the results of it were compared with the anatomical images for evaluation by an expert neuro-radiologist (MG). The abnormal regions were detected correctly for all patients without the failures of previous algorithm. The MRSI and DTI features of detected abnormal voxels with high probability of being cancerous (fuzzy membership bigger than 0.78) and their contralateral normal voxels were calculated reported in the following table. The detected values are in good agreement with those in the literature [2], [4]. The difference in the values may be related to the fact that the detected abnormal regions are composed of various amounts of necrosis and viable tumors while the reference values belong only to the viable tumors. In order to evaluate the extracted features statistically in differentiation of abnormality from normal tissue, different univariate logistic regression models were developed. NAA/Cr ratio was not discriminative (P-value = 0.470) while the other features were statistically significant (P-value<0.001). The FA was the best feature in differentiation of tumor and normal tissues with the highest odd ratio. The combination of DTI and MRSI features in discrimination of tumor and normal tissues were tested using logistic regression models and the best results are reported at the end of Table III. The improvement in odd ratios was found when Cho/Cr and FA features were combined.

Discussion

An unsupervised classifier based on MRSI and DTI features is able to detect brain abnormality automatically. It is shown that the integration of DTI and MRSI information improve the performance. This method would be helpful to detect tumors at early stages non-invasively and may be able to detect small tumors that are not detected using anatomical MRI. The proposed method can be further developed to estimate volumes of abnormal regions using 3D data for brain surgery or radiation therapy.

References

- [1] Magalhaes A et al., Acad Radiol 2005; 12(1):51-57. [3] Tropine A et al., J Magn Reson Imaging 2004; 20:905-912.
[2] Weybright P et al., AJR 2005; 185:8220-8228. [4] Sinha S et al., AJNR AM J Neuroradiol, 2002 ; 23:520-527.
[5] Torbatian Z et al., 3th Cairo International Biomedical Engineering Conference, Cairo, Egypt, Dec. 21-24 2006.



The DTI and MRSI values computed in detected abnormal and normal regions

Feature	Tumor- Mean (ranges)	Normal- Mean (ranges)
MDx10 ⁻⁶	1.56 (0.60-3.10)	0.83 (0.70-1.00)
FA	0.17 (0.08-0.33)	0.30 (0.13-0.45)
Cho/Cr	1.72 (0.80-4.07)	1.08 (0.78-1.91)
Cho/NAA	1.60 (0.31-5.71)	0.57 (0.19-1.51)
NAA/Cr	1.71 (0.41-5.97)	2.27 (0.82-8.16)